



PATIENT PRESENTING CLINICAL SIGNS

Gigi Morgan
Clinical Exam Findings: pale mucous membranes, flea allergy dermatitis, sq masses
Abnormal Labwork Values: Elevated ALT: 127, Elevated BUN/UREA: 46, Low Chloride: 108, Low HCT: 27.3, Low HGB: 11.8, Elevated MCHC: 43.2, Elevated Basophils: 0.11, Low Platelet: 53, Low RBD: 4.19, Elevated MCH: 28.2, Elevated MPV: 14, Low PCT: 0.07
Current Medications: Ivermectin

BREED Radiographic Findings:

Lab Mix

SEX

Spayed Female

AGE

6/6/2010

WEIGHT

45.5 lbs

1. Splenic mass suspected to be located in the head of the spleen, with suspected additional nodules associated with the splenic tail. A neoplasm such as a Malignant melanoma is considered most likely.
2. Small volume peritoneal effusion, likely representing hemorrhage associated with #1.
3. Multifocal soft tissue opaque pulmonary nodules. Unfortunately, this is most consistent with pulmonary metastatic neoplasia secondary to #1.
4. Intervertebral disc degeneration of the thoracolumbar vertebral column.

ULTRASONOGRAPHIC EXAMINATION OF THE ABDOMEN

Urinary System

The urinary bladder, trigone, and pelvic urethra are normal in thickness and the mucosal surface is smooth. The bladder lumen is moderately distended with anechoic urine. No masses, inflammatory changes or calculi are observed. Ureteral papillae and visualized portion of the proximal urethra, visible to a depth of 1-2 cm, are normal.

The left kidney is normal size (6.23 cm in length); normal shape and architecture with smooth peripheral margins. There is a normal 1:3 cortex to medulla ratio with minimal to mild loss of corticomedullary distinction. There is no evidence of pyelectasia, nephroliths, infarcts or hydronephrosis. Renal vasculature is normal.

The right kidney is normal size (7.09 cm in length); normal shape and architecture with smooth peripheral margins. There is a normal 1:3 cortex to medulla ratio with minimal to mild loss of corticomedullary distinction. There is no evidence of pyelectasia, nephroliths, infarcts or hydronephrosis. Renal vasculature is normal.

Adrenal Glands

The left adrenal gland is normal size (0.52 cm at cranial pole) (0.60 cm at caudal pole) (2.22 cm in length); normal shape; homogenous parenchyma. The glandular echogenicity and detail are unremarkable. Capsule, cortex, and medullary definition are normal. The phrenicoabdominal vein and surrounding vasculature are normal.

The right adrenal gland is normal size (1.09 cm at cranial pole) (0.74 cm at caudal pole) (1.93 cm in length); normal shape; homogenous parenchyma. The glandular echogenicity and detail are unremarkable. Capsule, cortex, and medullary definition are normal. The phrenicoabdominal vein and surrounding vasculature are normal.

INTERPRETED BY

Andrea Nicastro,
DVM, Diplomate
ACVIM (Small Animal
Internal Medicine)

IMAGING PERFORMED BY

Andrea Nicastro,
DVM, Diplomate
ACVIM (Small Animal
Internal Medicine)

HOSPITAL NAME

Flowerstown AH

REFERRING VET

Dr. Randinelli

INVOICE

11023

DATE

6/3/22



PATIENT

Gigi Morgan

SPECIES

Canine

BREED

Lab Mix

SEX

Spayed Female

AGE

6/6/2010

WEIGHT

45.5 lbs

INTERPRETED BY

Andrea Nicastro,
DVM, Diplomate
ACVIM (Small Animal
Internal Medicine)

IMAGING PERFORMED BY

Andrea Nicastro,
DVM, Diplomate
ACVIM (Small Animal
Internal Medicine)

HOSPITAL NAME

Flowertown AH

REFERRING VET

Dr. Randinelli

INVOICE

11023

DATE

6/3/22

Spleen

The spleen is enlarged with irregular peripheral contours. Two coalescing, heterogenous, cavitated masses are arising from the parenchyma, the larger mass measuring approximately 5.00 cm in its longest dimension. A 3.00 cm to 3.50 cm irregular clot is adhered to the mass. The mesentery in this region is hyperechoic. The remaining splenic parenchyma is mottled in appearance. Splenic vasculature is normal with no evidence of thrombosis.

Liver

The liver is subjectively normal in size with normal curvilinear peripheral contours. The parenchyma is slightly mottled in appearance. No distinct focal lesions are observed. Vascular and biliary tracts are of normal volume with no evidence of congestion

The gall bladder wall is mildly distended. The lumen is filled with aggregated, partially dependent, hyperechoic sludge, which is difficult to discern from the wall itself. The cystic and common bile ducts are normal/not seen.

Gastrointestinal

The stomach and intestine are free of stasis and exhibit normal peristaltic activity. The gastric lumen is mildly to moderately distended with ingesta. The gastric wall and pylorus are normal in thickness with a normal layering pattern. The pyloric outflow tract is patent. The small intestinal lumen is segmentally dilated with chyme. The small intestinal wall thickness is normal with a normal layering pattern and appropriate mural detail. Discreet masses are not identified. The colonic wall is normal. No obstructive disease is noted.

Pancreas

A portion of the pancreas is obscured by the splenic pathology and gastric distention. In the visualized portions no obvious abnormalities are seen.

Free Abdomen

A moderate amount of echogenic free fluid is present. The abdominal lymph nodes are normal/not visible.

Other

A brief echocardiogram reveals no evidence of pericardial effusion or obvious right atrial/auricular mass.

ULTRASONOGRAPHIC FINDINGS



PATIENT

Primary Findings

Gigi Morgan

- Ruptured splenic mass with adhered clot, regional peritonitis and suspected hemoabdomen. Hemangiosarcoma is a top differential with a lower possibility of a benign tumor, particularly in light of the suspected pulmonary metastases.

SPECIES

Canine

- The hepatic parenchymal changes are nonspecific and are most consistent with benign age-related change. However, metastatic disease cannot be completely excluded.

BREED

Lab Mix

Secondary Findings

SEX

- Gall bladder sludge, non-mucocele
- Minor, bilateral age-related renal changes

Spayed Female

AGE

6/6/2010

INTERPRETATION OF THE FINDINGS & FURTHER RECOMMENDATIONS

- Given that pulmonary metastatic disease is suspected on thoracic radiographs (per radiologist's report), palliative/symptomatic care (i.e., Yunnan baiyao) is recommended.

WEIGHT

45.5 lbs

INTERPRETED BY

Andrea Nicastro,
DVM, Diplomate
ACVIM (Small Animal
Internal Medicine)

IMAGING PERFORMED BY

Andrea Nicastro,
DVM, Diplomate
ACVIM (Small Animal
Internal Medicine)

HOSPITAL NAME

Flowertown AH

REFERRING VET

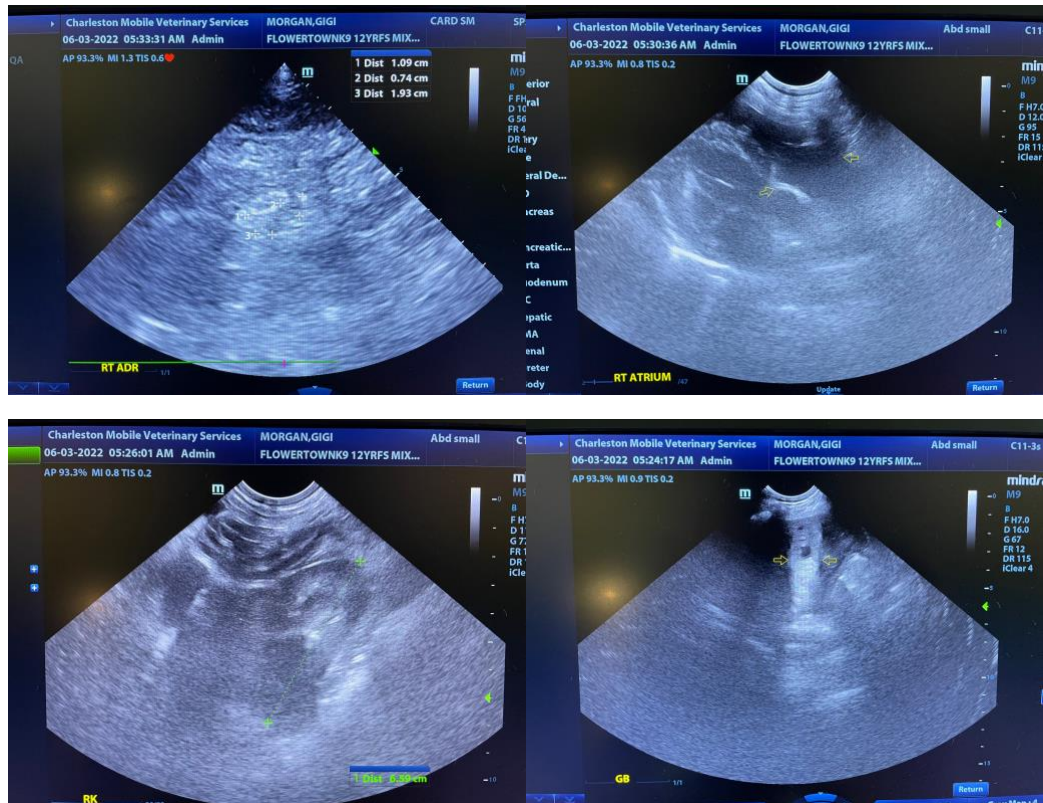
Dr. Randinelli

INVOICE

11023

DATE

6/3/22





PATIENT

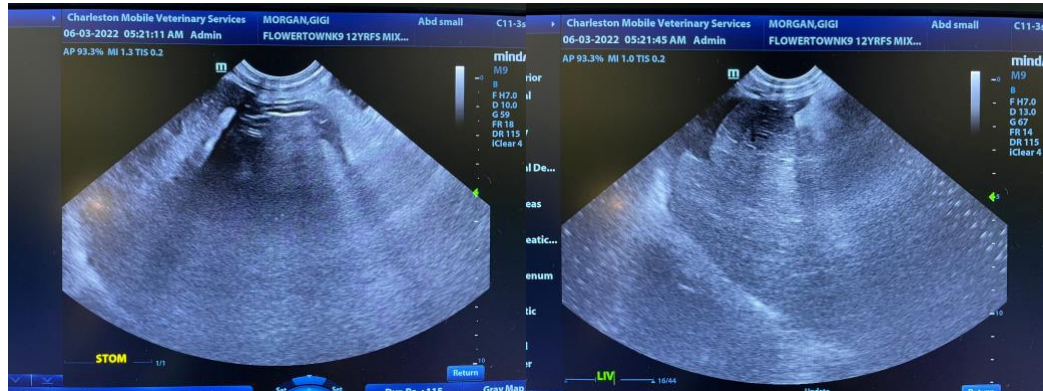Gigi Morgan

SPECIES

Canine

BREED

Lab Mix



SEX

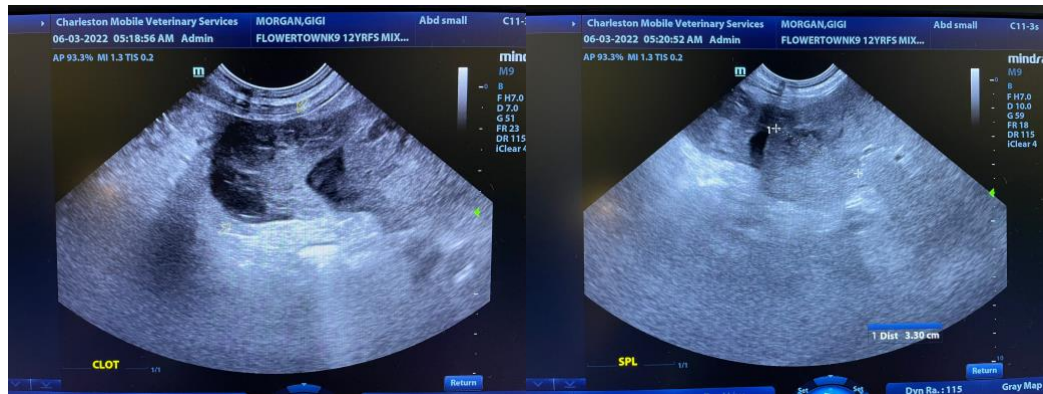
Spayed Female

AGE

6/6/2010

WEIGHT

45.5 lbs

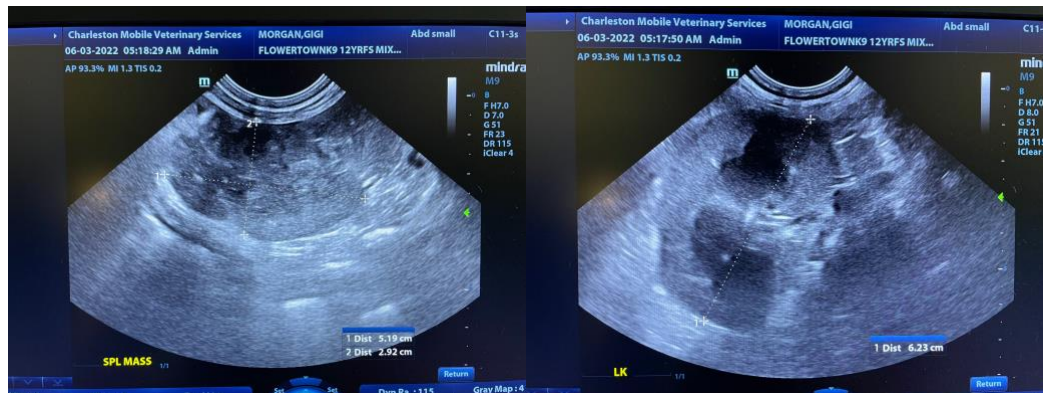


INTERPRETED BY

Andrea Nicastro,
DVM, Diplomate
ACVIM (Small Animal
Internal Medicine)

IMAGING PERFORMED BY

Andrea Nicastro,
DVM, Diplomate
ACVIM (Small Animal
Internal Medicine)



HOSPITAL NAME

Flowertown AH

REFERRING VET

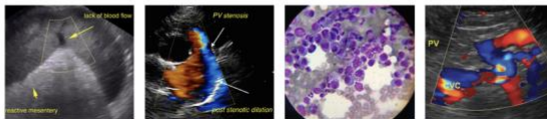
Dr. Randinelli

INVOICE

11023

DATE

6/3/22



PATIENT

Gigi Morgan

SPECIES

Canine

BREED

Lab Mix

SEX

Spayed Female

AGE

6/6/2010

WEIGHT

45.5 lbs

INTERPRETED BY

Andrea Nicastro,
DVM, Diplomate
ACVIM (Small Animal
Internal Medicine)

**IMAGING
PERFORMED BY**

Andrea Nicastro,
DVM, Diplomate
ACVIM (Small Animal
Internal Medicine)

HOSPITAL NAME

Flowertown AH

REFERRING VET

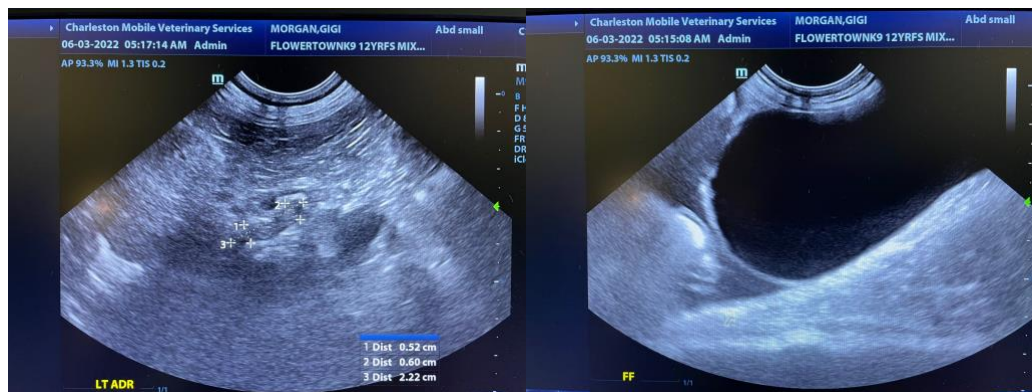
Dr. Randinelli

INVOICE

11023

DATE

6/3/22



The information and recommendations provided are based on the images presented by the referring veterinarian/sonographer. No evaluation can be communicated regarding pathology that was not visible in the image/video clips provided.

Thank you for this referral. If the clinical or image interpretation does not parallel your findings or if I can be of any further assistance, please contact me.

Andrea Nicastro, DVM, Diplomate DACVIM (Small Animal Internal Medicine)
info@SonoPath.com